

# VERTEBRAL AUGMENTATION:

## *Effective, minimally invasive treatment for spine fractures*

Vertebral compression fractures (VCFs) are common. They frequently occur in postmenopausal women, patients on steroid therapy, and in patients with bone metastasis in the spine or multiple myeloma.

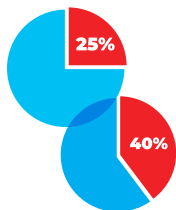
### VCFs: Prevalence and Risks



**34,000,000 Americans**

have low bone mass, placing them at risk for osteoporosis.<sup>1</sup>

Women are **4X more likely** than men to develop osteoporosis<sup>1</sup>



VCFs are the most common fracture in patients with osteoporosis, affecting **25% of all postmenopausal women** and **40% of all women over 80**<sup>1</sup>

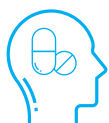Patients with a single thoracic vertebral compression are **5X more likely** to suffer another fracture.<sup>1</sup>



A single fracture at any vertebrae **increases mortality risk by 15%**<sup>2</sup>

### VCFs: Pharmacological Treatment

NSAIDs, often prescribed for pain control of VCFs, have **gastric toxicity** and an **increased risk of cardiac events** for patients with hypertension and coronary artery disease.<sup>3</sup>



Opioids may provide strong relief when NSAIDs are inadequate; however there is a **major risk of dependency**.

### VCFs: Treatment with Vertebroplasty and Kyphoplasty

#### VERTEBROPLASTY

- Up to **90% success rate**<sup>4</sup> in treating osteoporotic VCFs.
- When compared to traditional treatment, **patients treated with vertebroplasty had statistically significant improvements in pain relief.**<sup>5</sup> **90% of patients** experienced **pain relief** and **improved mobility** at 24 hours post vertebroplasty.<sup>6</sup>

#### KYPHOPLASTY

- A retrospective, 2-year single center study<sup>7</sup> demonstrates that kyphoplasty was shown to:



Pain



Need for pain medication



Ability to walk without support

- **7 out of 10** patients (approximately) achieved complete pain relief at 1 week and more than **8 out of 10** after 3-6 months, and was maintained for at least 2 years.<sup>7</sup>

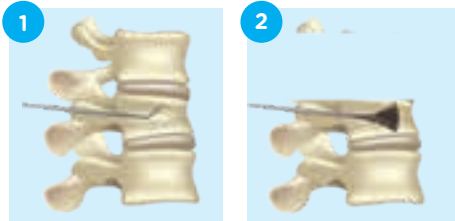
- Vertebral height restoration of  $\geq 10\%$  was achieved in 90% of fractures, along with normalization of morphologic shape.<sup>7</sup>

- 4 year results show that kyphoplasty patients experience **lower mortality and morbidity** than VCF patients who receive conservative management.<sup>8</sup>

- Patients undergoing kyphoplasty for VCF were **37% less likely to die** than patients with VCF who did not have the procedure.<sup>9</sup>

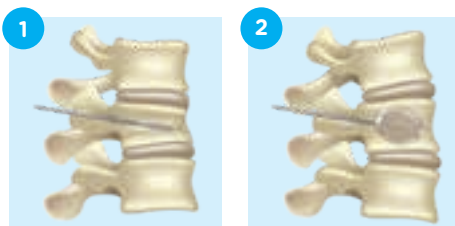
# VERTEBRAL AUGMENTATION:

## *Vertebroplasty and Kyphoplasty procedures*



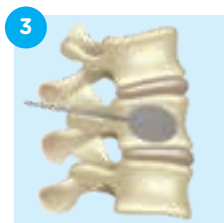**Instrument Inserted**

**Cement Filled**



**Balloon Inserted**

**Balloon Inflated**



**Cement Filled**

**Vertebroplasty** is performed on an outpatient basis, usually under local anesthesia. During the procedure, the interventional radiologist uses fluoroscopy to position a needle into the fractured vertebra. A special fast-drying bone cement is then injected into the bone to stabilize the fracture.

**Kyphoplasty** (also called balloon kyphoplasty) is also performed on an outpatient basis. During the procedure, cannula is placed directly in the fractured vertebrae. A balloon is then inserted into the disc and inflated to correct the loss of height suffered during the fracture. The cavity made by the balloon is then filled with a fast-drying bone cement.

Either procedure typically takes less than an hour for each fracture, and the patient is usually able to return home the same day. The vast majority of patients have reported that vertebroplasty and kyphoplasty provide immediate pain relief and has improved their quality of life.<sup>10</sup>

**The physicians of Vascular & Interventional Specialists of America are among the most experienced in the region at performing interventional radiology procedures. If you are interested in learning more about vertebral augmentation or consulting with us regarding a patient, please call 205-905-8411.**

1. SOURCE: American Association of Neurological Surgeons website  
2. Cooper C, Atkinson EJ, Jacobsen SJ, O'Fallon WM, Melton LJ, 3rd Population-based study of survival after osteoporotic fractures. *Am J Epidemiol*. 1993;137(9):1001-1005  
3. Bavy AA, Khaliq A, Gong Y, Handberg EM, Cooper-Dehoff RM, Pepine CJ. Harmful effects of NSAIDs among patients with hypertension and coronary artery disease. *Am J Med*. 2011;124(7):614-620.  
4. Deramond H, Depriester C, Galibert P, Le Gars D. Percutaneous vertebroplasty with polymethyl methacrylate. Technique, indications, and results. *Radiol Clin North Am*. 1998;36:533-46.  
5. Tian, Jing et al. The clinical efficacy of vertebroplasty on osteoporotic vertebral compression fractures: a meta-analysis. *Int J Surg*. 2014 Dec;12(12):1249-53. doi: 10.1016/j.ijsu.2014.10.027. Epub 2014 Oct 28.  
6. Jensen ME, Evans AJ, Mathis JM, Kallmes DF, Cloft HJ, Dion JE. Percutaneous polymethylmethacrylate vertebroplasty in the treatment of osteoporotic vertebral body compression fractures: technical aspects. *AJNR Am J Neuroradiol*. 1997;18:1897-904.

7. Ledlie JT, Renfro MB. Kyphoplasty treatment of vertebral fractures: 2-year outcomes show sustained benefits. *Spine J*. 2006;31:57-64  
8. Edidin AA, Ong KL, Lau E, Kurtz SM. Morbidity and Mortality after Vertebral Fractures: Comparison of Vertebral Augmentation and Non-Operative Management in the Medicare Population. *Spine (Phila Pa 1976)*. 2015 Aug 1;40(15):1228-41. doi: 10.1097/SPR.0b013e31826020845  
9. Edidin AA, Ong KL, Lau E, Kurtz SM. Mortality risk for operated and nonoperated vertebral fracture patients in the medicare population. *J Bone Miner Res*. 2011 Jul;26(7):1617-26. doi: 10.1002/jbmr.353. PubMed PMID: 21308780.  
10. McGirt HJ, Parker SL, Wolinsky JP, Witham TF, Bydon A, Gokaslan ZL. Vertebroplasty and kyphoplasty for the treatment of vertebral compression fractures: an evidenced-based review of the literature. *Spine J*. 2009;9(6):501-508